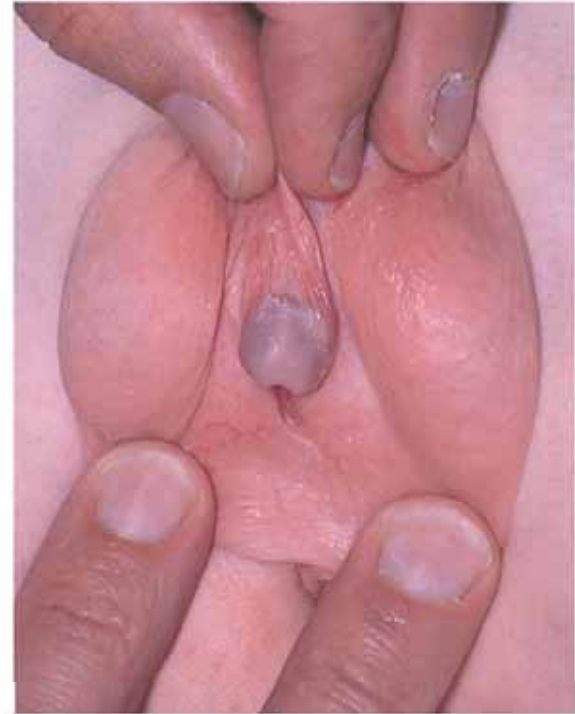
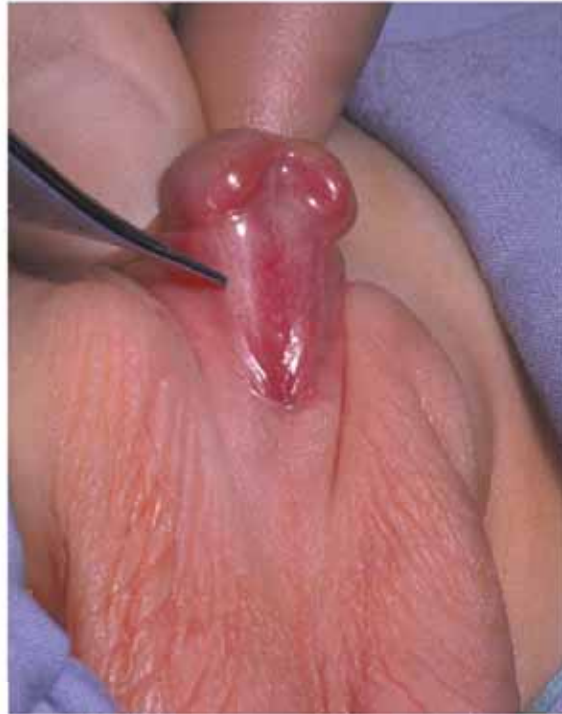
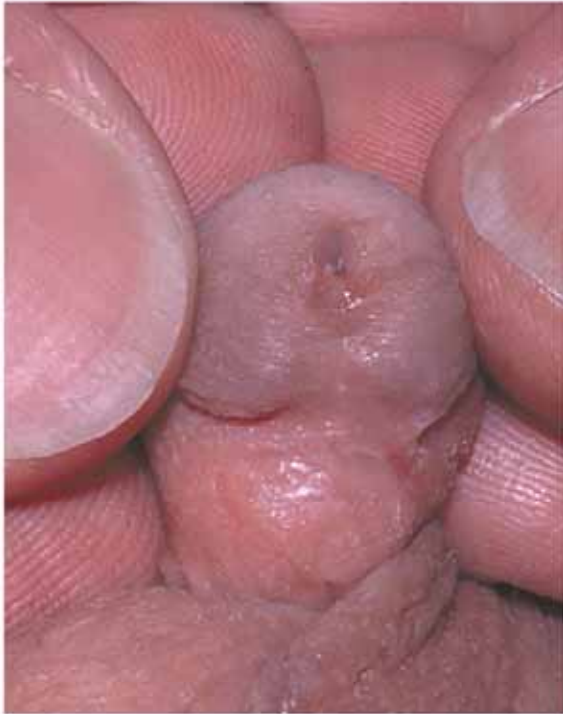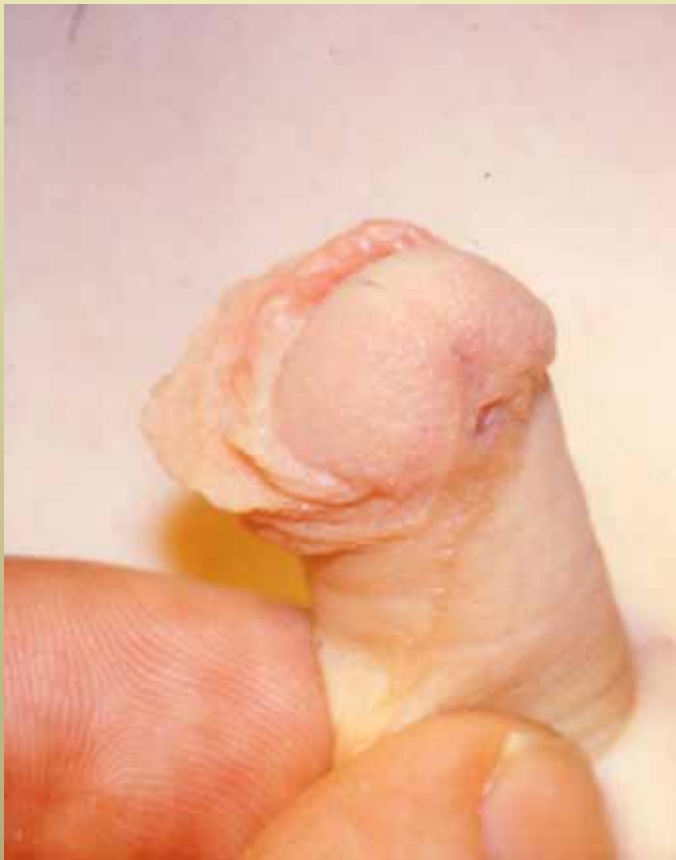# Hypospadias – Historical Aspects

A.R.Mundy & D.E.Andrich  
Institute of Urology  
London

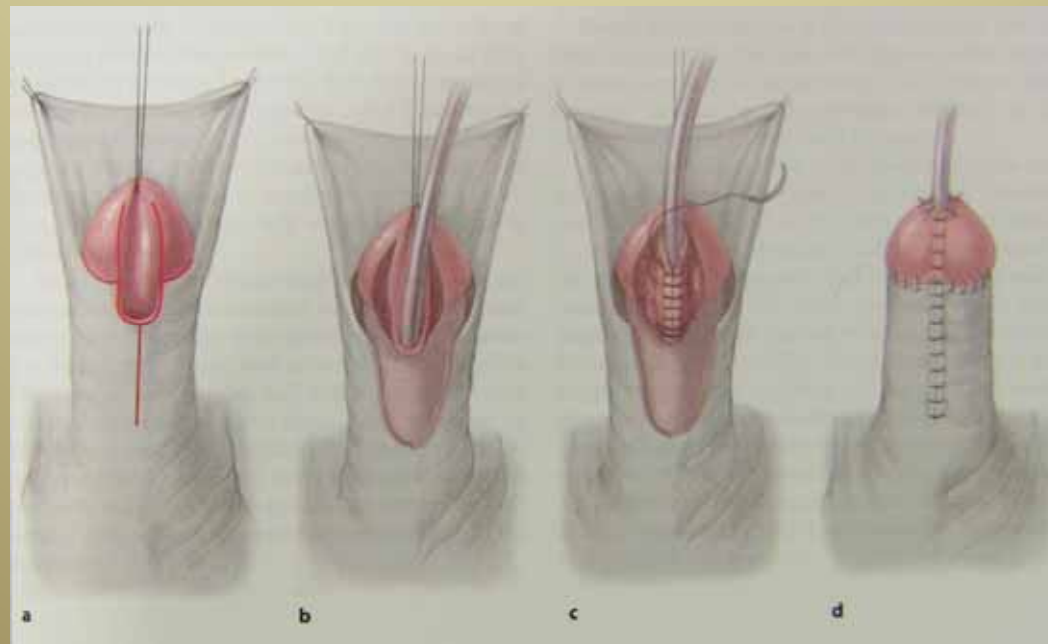
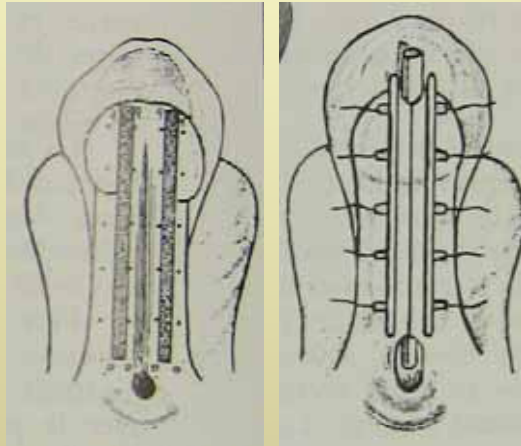
# What Is Hypospadias?



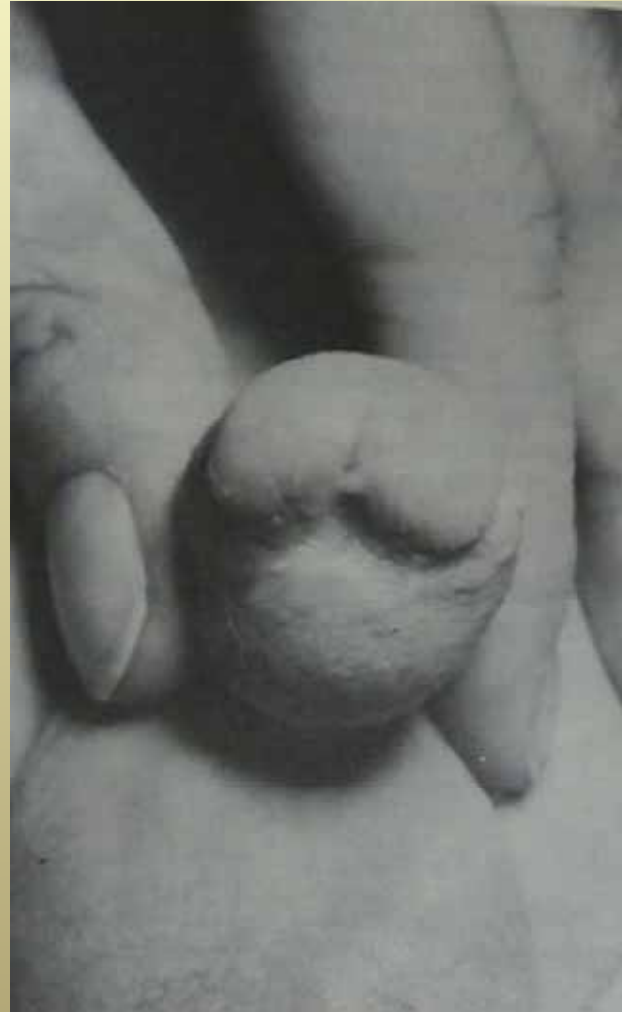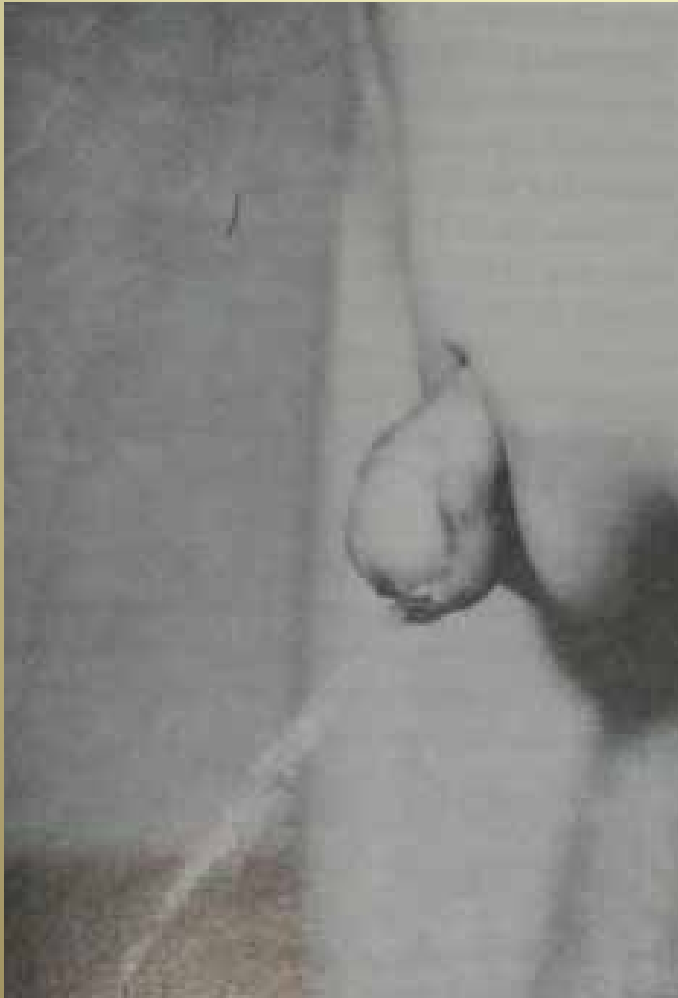Not In Asia



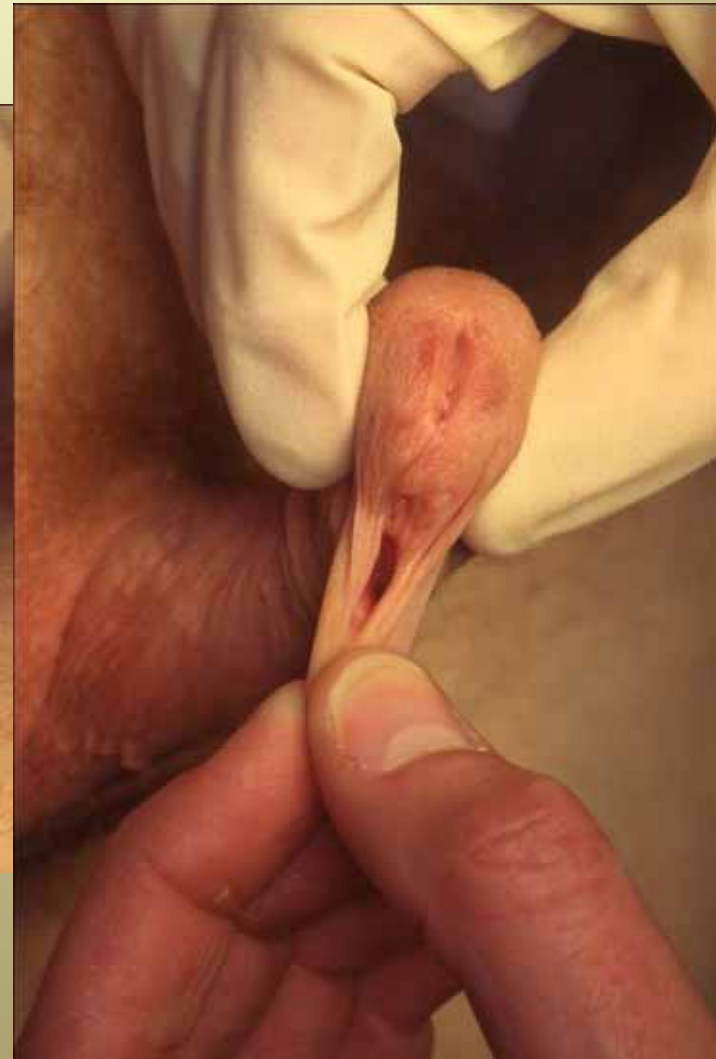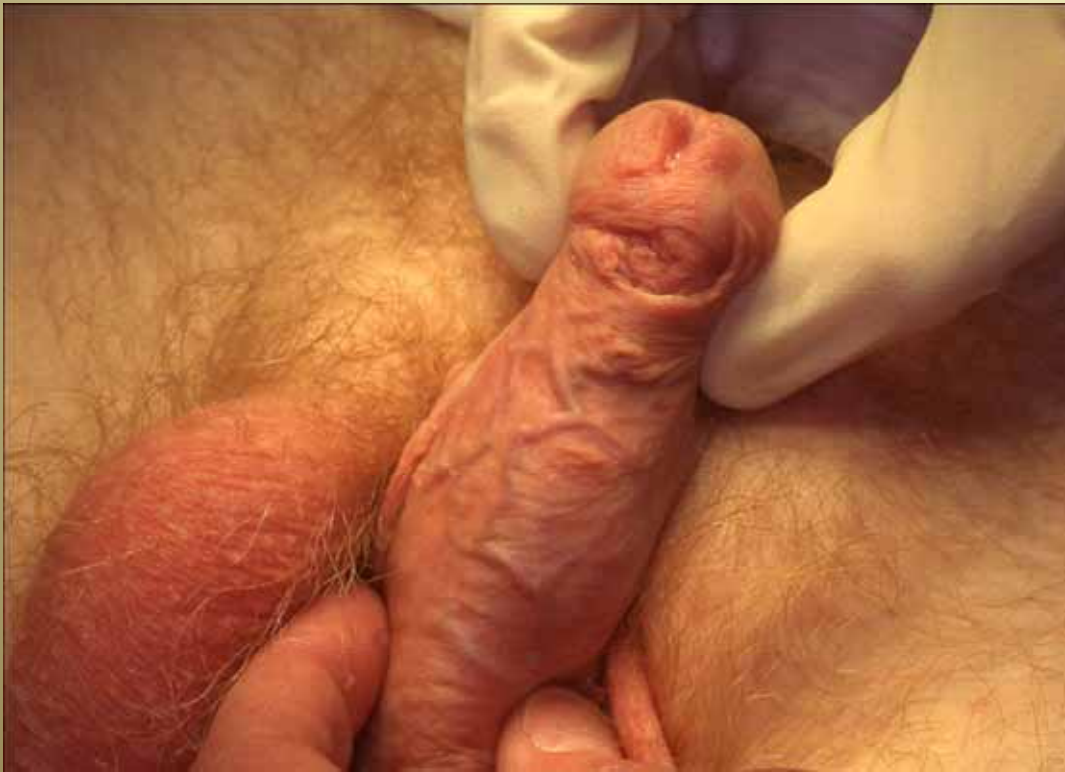# (Thiersch) Duplay



# Excellent Results – Hendren (1980)



# Meatal Site



# Changing Attitudes

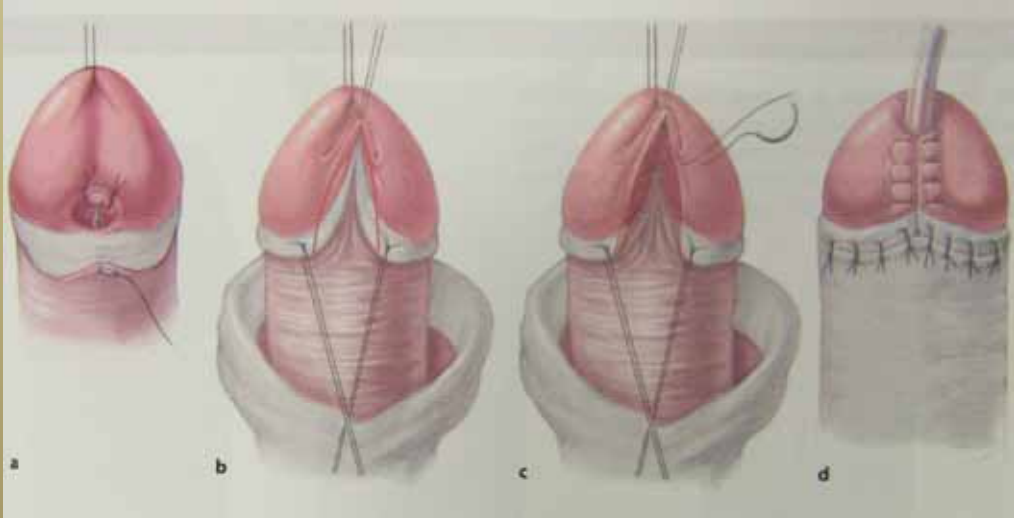
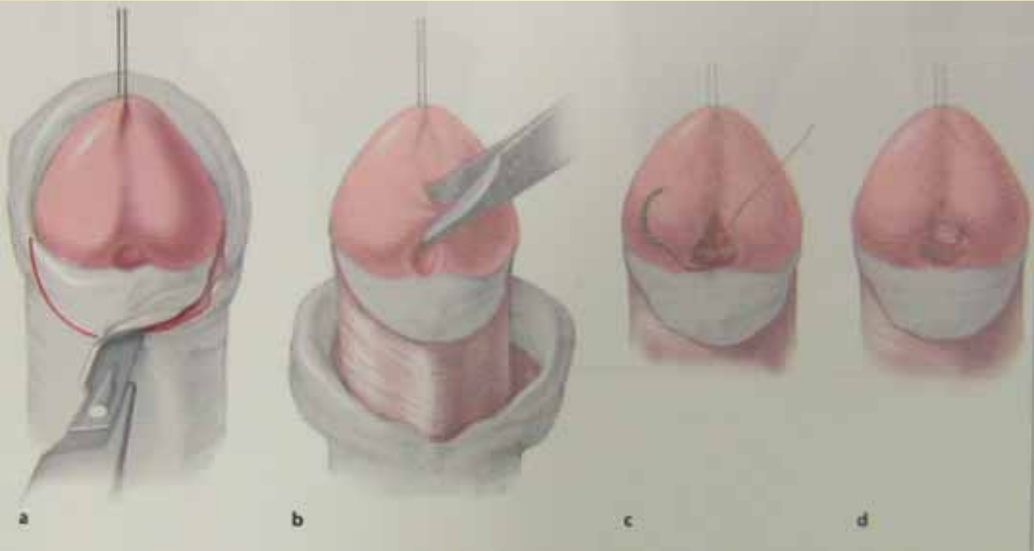
Was

- No real attention to the glans and meatus

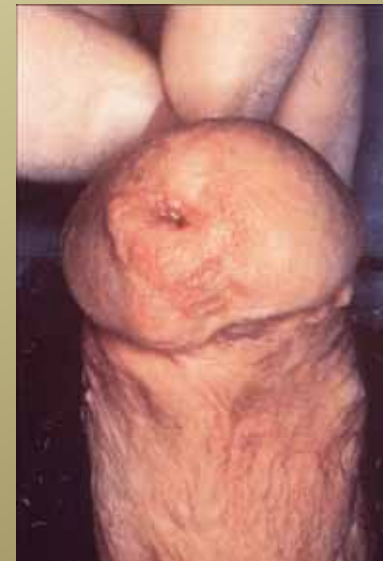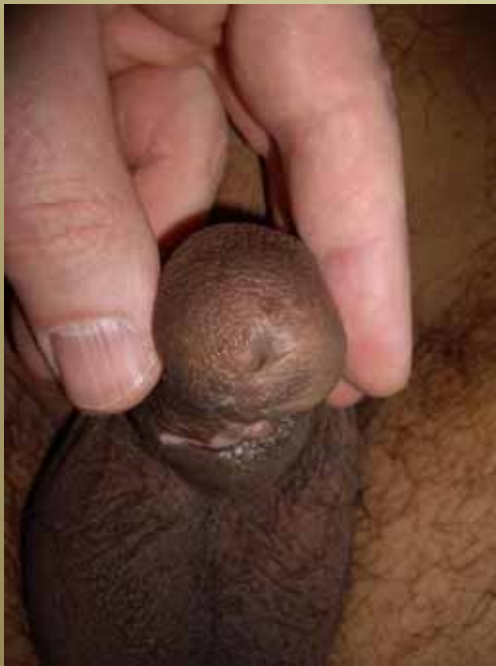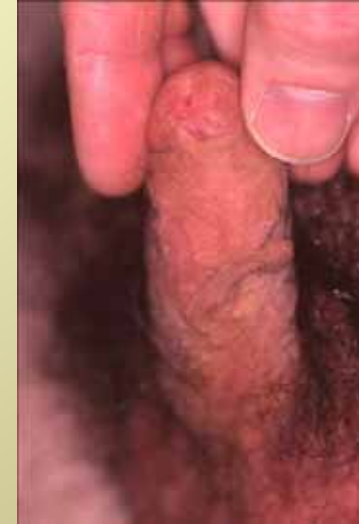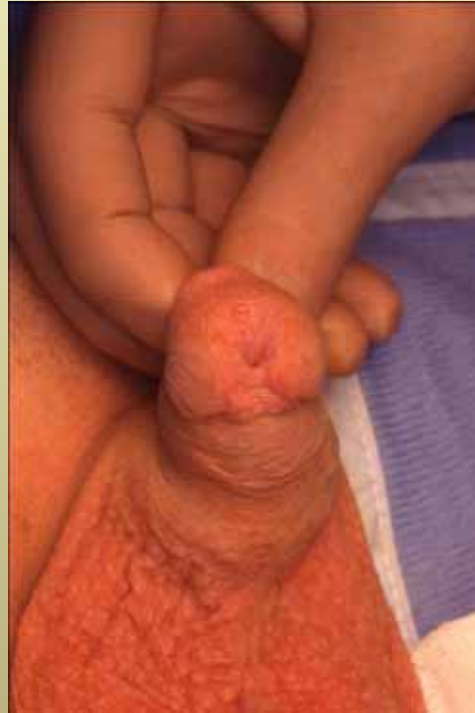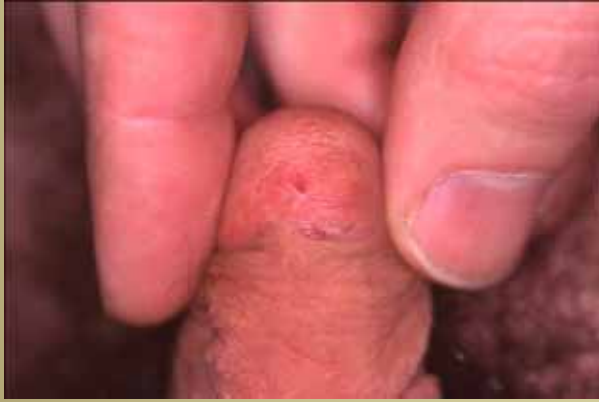Now

- Mainly attention to the glans and meatus

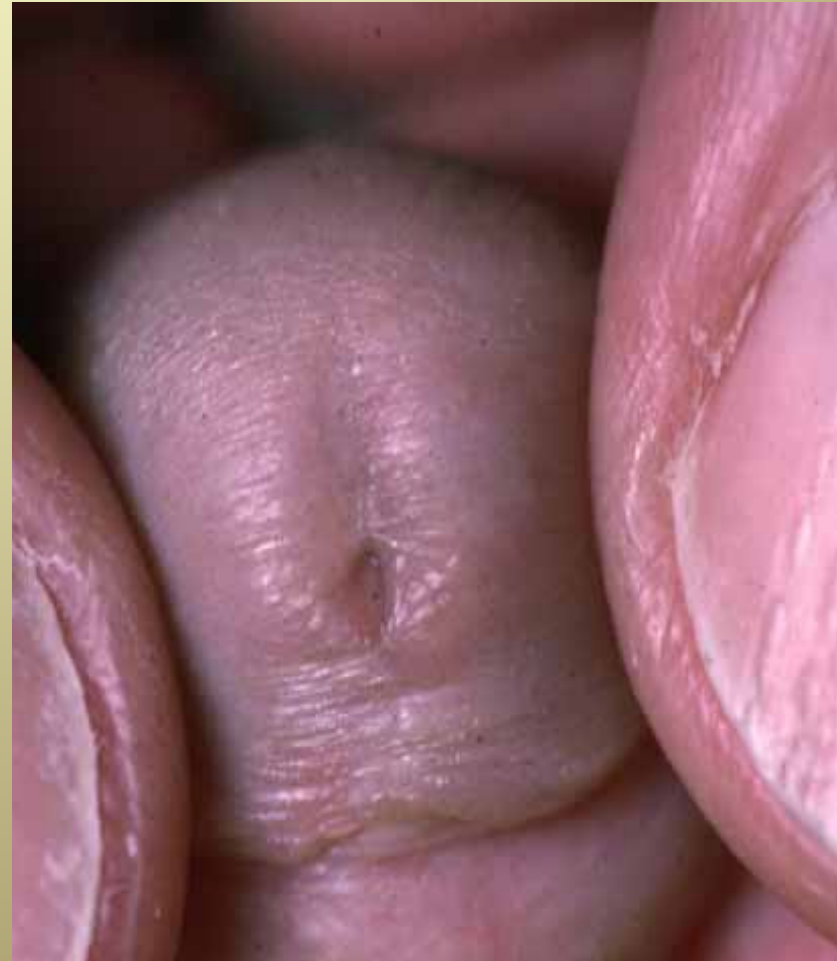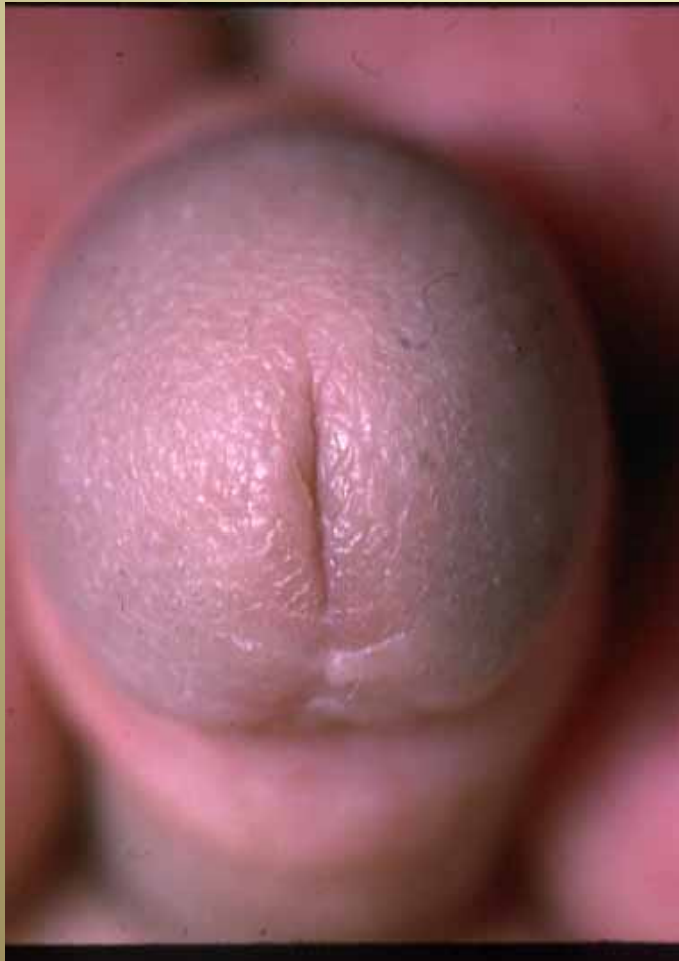# MAGPI



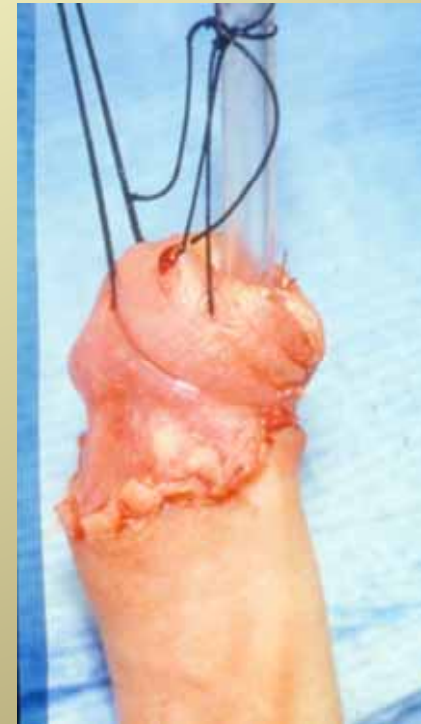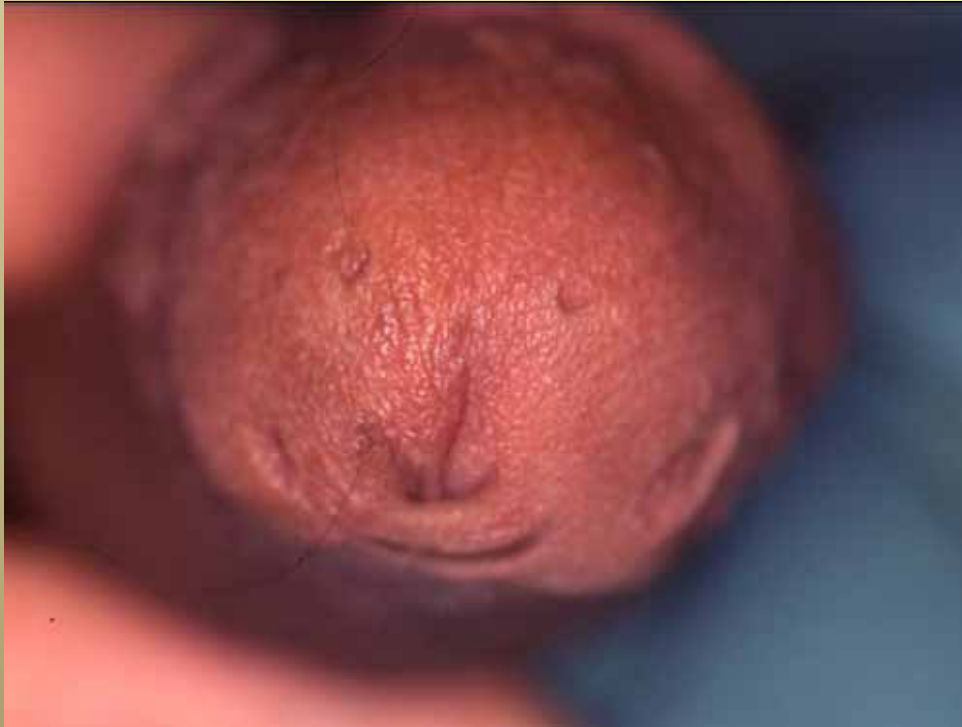# MAGPI



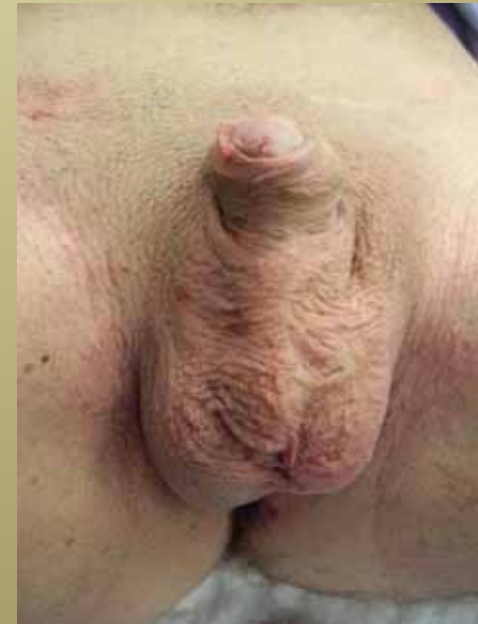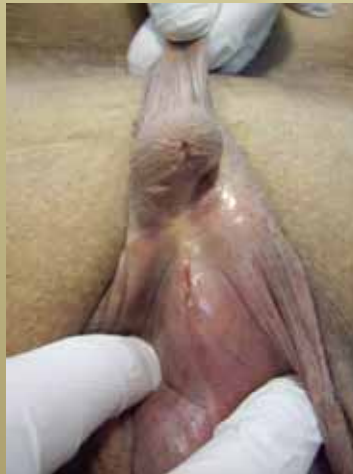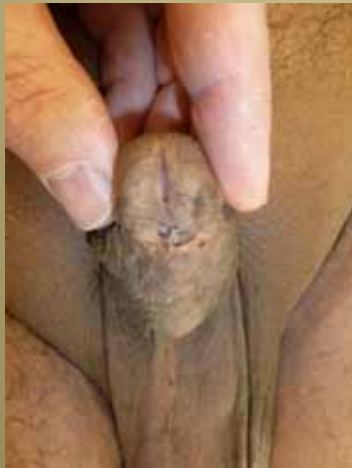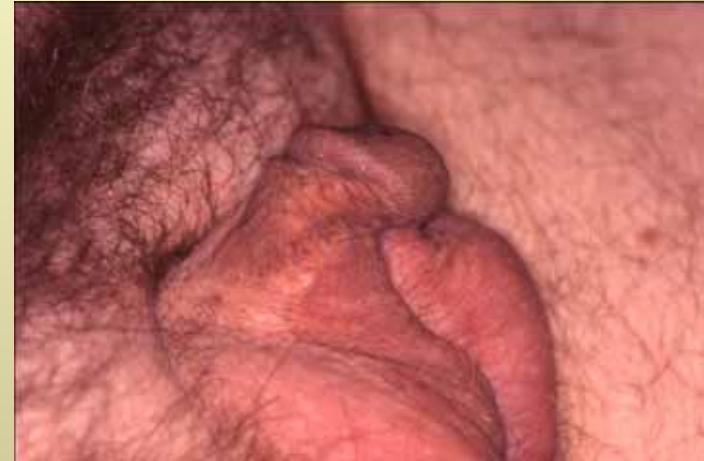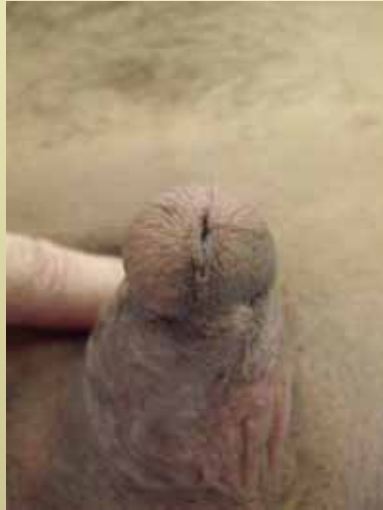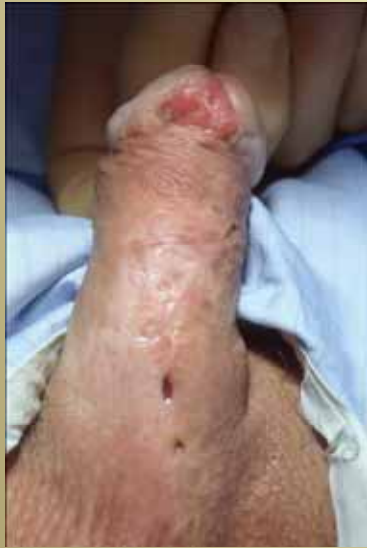# 'Snodgrass' - optical illusion



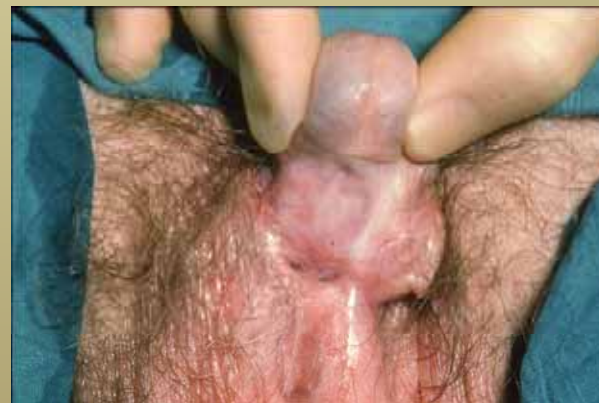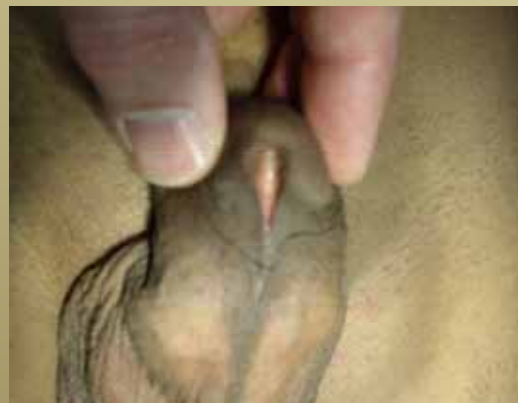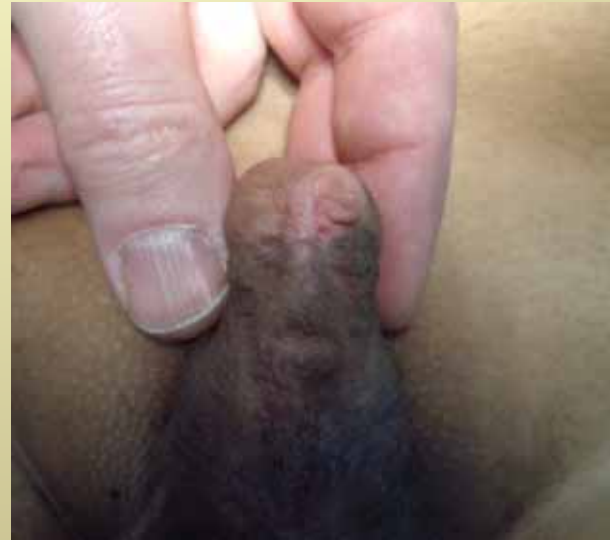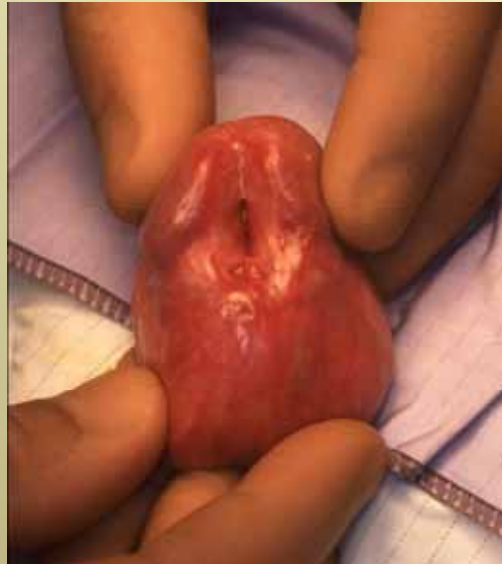# Unnecessary Trauma



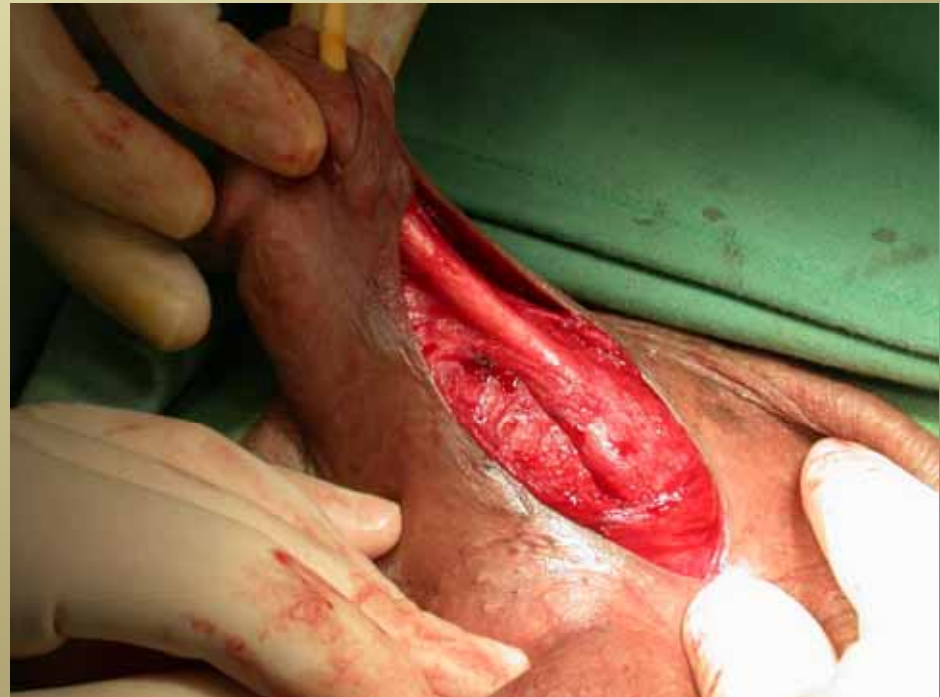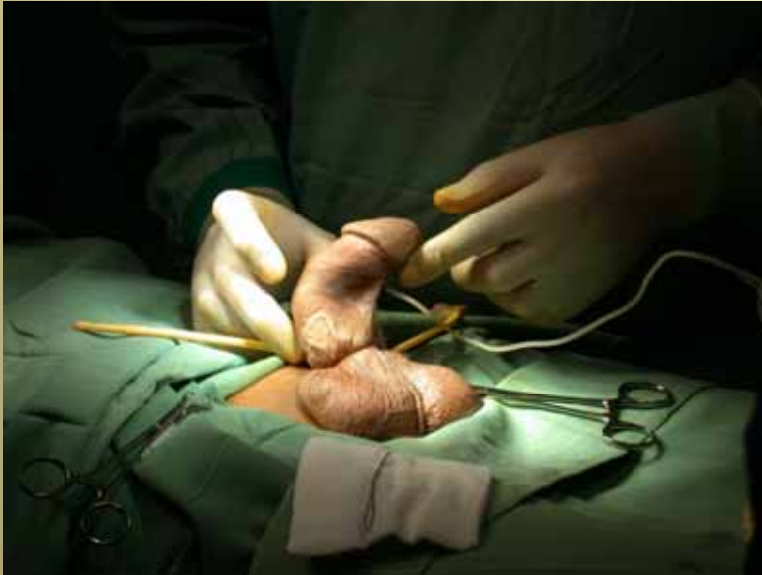# Post-Operative - General



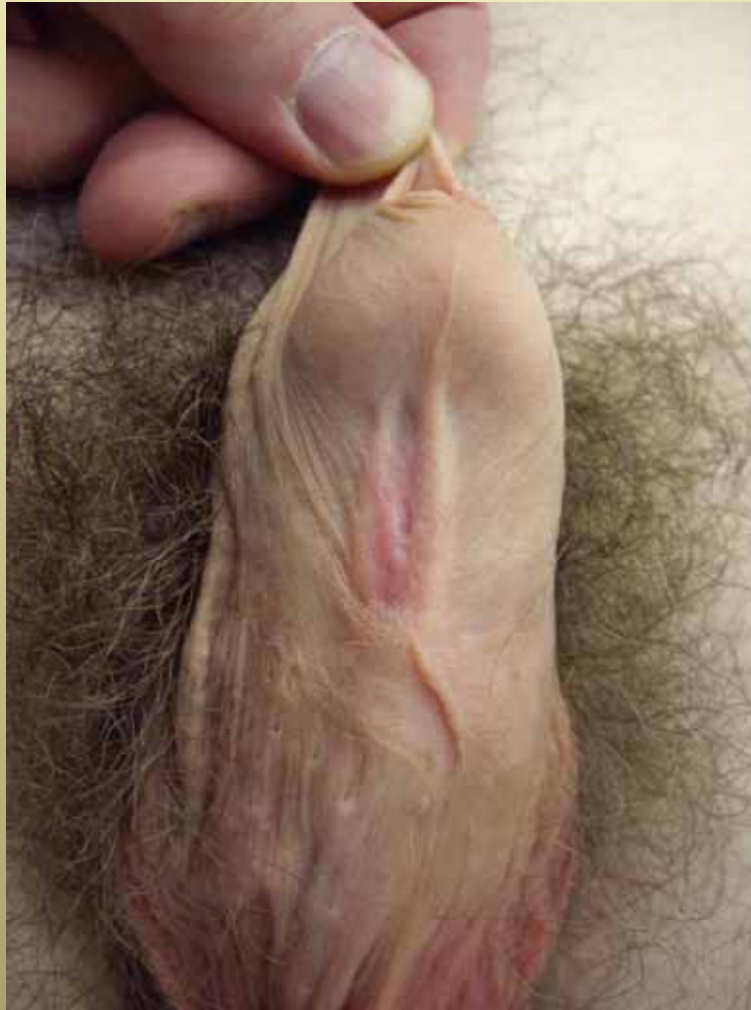# Glans Cleft



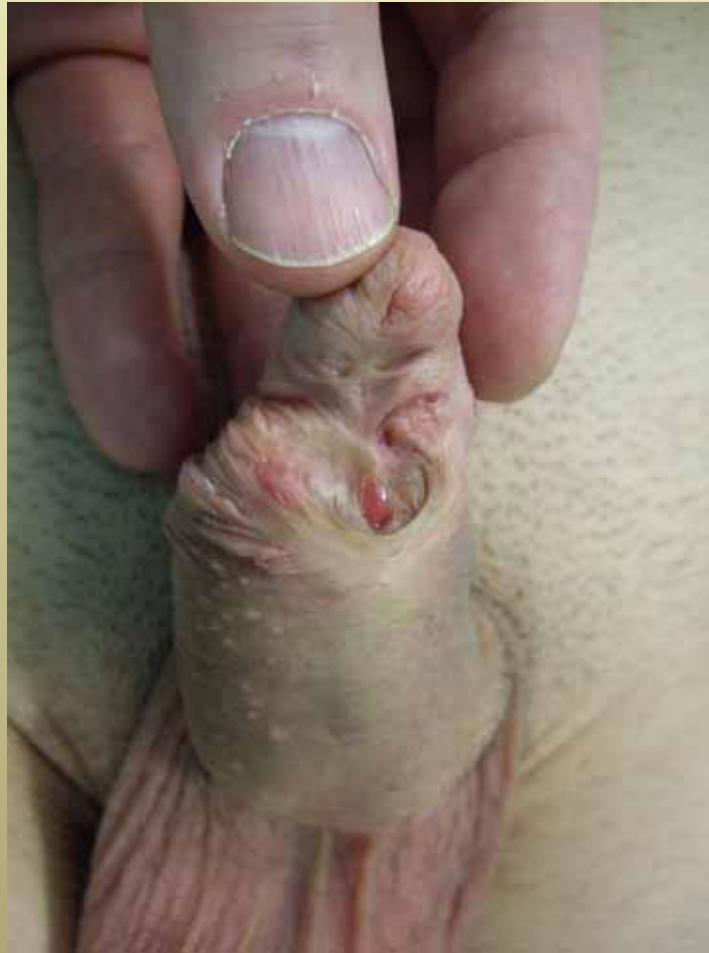# Short Urethra



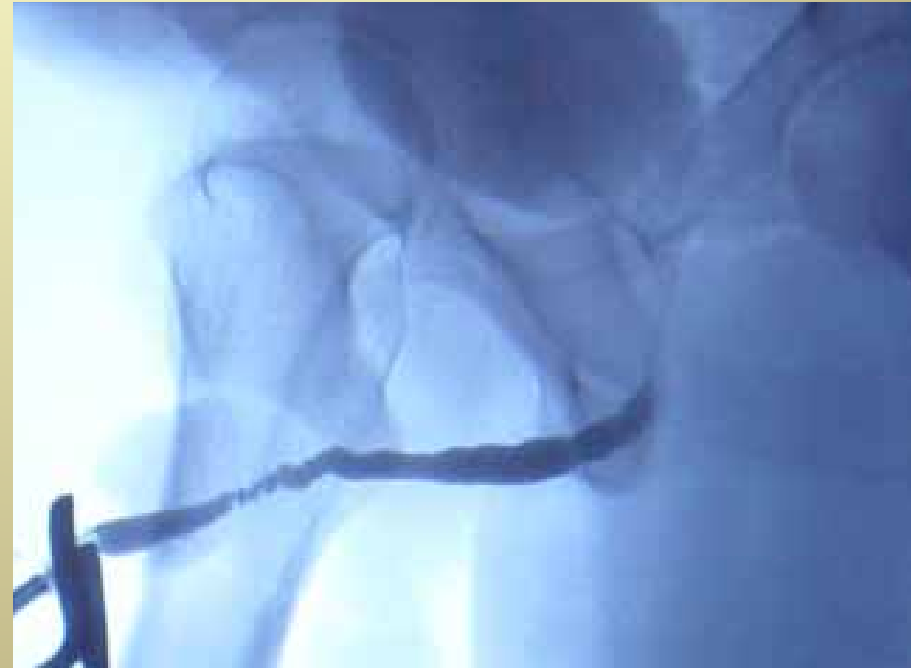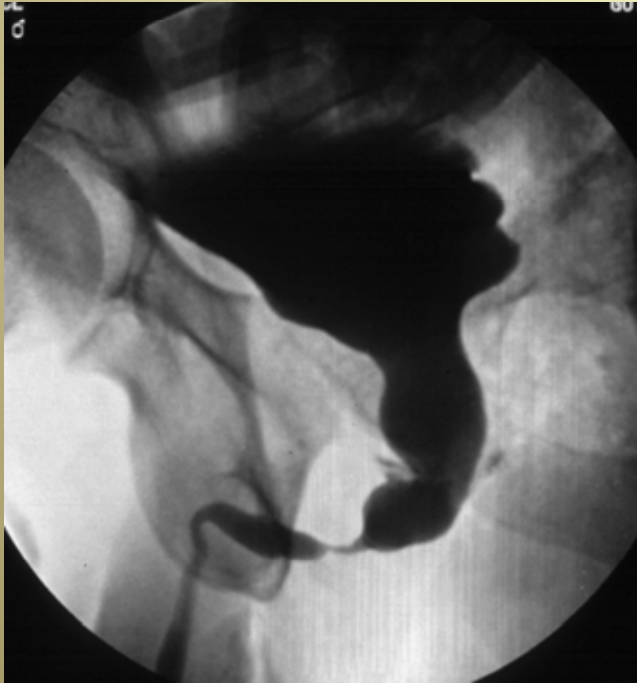# Deficient Dartos



??



# The Urethra



# What Makes It Difficult? - 1

- Small glans
- Traumatic soft tissue loss
- No dartos
- No spongiosum
- Previous graft or flap requiring excision
- Significant chordee
- Stricture in previous urethroplasty >3cm
- Associated lichen sclerosus

## What Makes It Difficult? - 2

- Small penis
- Large fistula or multiple fistulae
- Scarred penile shaft
- Associated bulbar stricture
- Associated peno-scrotal transposition
- Associated obesity

# Problems

- How to test the list
- How to quantify e.g. 'small', 'deficient'
- How to score severity:
  - Groups of problems = Grade 1,2 or 3
  - Score each problem 1,2 3 etc to give a total